Discontinuities in the Dorsal Lateral Geniculate Nucleus Corresponding to the Optic Disc: A Comparative Study [1]

J. H. KAAS, R. W. GUILLERY AND J. M. ALLMAN
Laboratory of Neurophysiology and Department of Anatomy, University of Wisconsin, Madison, Wisconsin 53706

ABSTRACT A cylindrical cellular discontinuity commonly occurs in lateral geniculate layers that are innervated by the contralateral eye. Such a discontinuity has been found in a variety of mammalian species, including carnivores, primates, a rodent and a marsupial. Electrophysiological evidence obtained from some of these species shows that the discontinuity corresponds to the blind spot. It is concluded that the representation of the retina within the lateral geniculate nucleus is extremely accurate, since the retinal receptor layer and the geniculate layers have corresponding holes.

Two possible mechanisms that would demand such a discontinuity are considered. One is an intralaminar mechanism in which the cells in each lamina accurately reflect the distribution of retinal receptors; the other is an interlaminar mechanism in which the representations of the homonymous hemiretinae are so accurately aligned that the optic disc must be represented by a cellular discontinuity.

It has been shown that there is a small, more or less cylindrical, cell free zone within layer A of the lateral geniculate nucleus of the domestic cat (Thuma, '28; Guillery, '67) and microelectrode recordings have established that this cellular discontinuity corresponds to the optic disc (Guillery and Kaas, '71). That is, the nasal retina sends an orderly projection to the contralateral layer A, the receptor surface of the nasal retina has a hole in it at the optic disc, and layer A has a corresponding hole, or cellular discontinuity. Neurons immediately surrounding this cellular discontinuity can be activated by stimulating parts of the retina next to the optic disc. It is reasonable to suppose that in other mammals the geniculate layers that are innervated by the hemiretina containing the disc may show a similar discontinuity.

Discovery of cellular discontinuities in other mammals would allow several deductions about the organization of the lateral geniculate nucleus. First, since the optic disc is in the hemiretina that projects contralaterally, any geniculate layer with a discontinuity must be innervated by the contralateral hemiretina. Secondly, since the discontinuity occurs as a cell free column through some of the layers, the orientation of this column indicates how the "lines of projection," which represent single points in the visual field (Bishop et al., '62) are oriented in a part of the nucleus. Thirdly, the discontinuity allows certain deductions about the visuotopic organization of the lateral geniculate nucleus, since a point in the retina can be related precisely to a column in the nucleus. Thus, it is possible to obtain a considerable amount of information about the way in which the retinal projections to the lateral geniculate nucleus are organized by studying the normal nucleus and the position of the discontinuities. Such information may be especially useful for species for which experimental investigations are difficult or the number of available individuals limited.

The occurrence of a cellular discontinuity suggests that there is an extremely accurate representation of the retina within each geniculate layer. The present study was undertaken to determine the extent to which such evidence of an accurate representation can be found in a variety of dif-

[1] Supported by grants 1 P01 HD 03352, 5 P01 NS 06225, 5-T01-NS-05326, and R01 NS 06662 from the U.S.P.H.S.

ferent mammals and to find whether a cellular discontinuity could provide a useful landmark for future comparative and experimental studies.

MATERIALS AND METHODS

Most of the brains that were studied are from the normal brain collection of the Laboratory of Neurophysiology. They were embedded in celloidin, cut in frontal, sagittal or horizontal planes as 30 μ sections and stained with thionin. We also studied the brains of six grey squirrels (*Sciurus carolinensis*), six owl monkeys (*Aotus trivirgatus*), three macaque monkeys (*Macaca mulatta*) and one marsupial phalanger (*Trichosurus vulpecula*) by electrophysiological methods. Microelectrode recordings were obtained from the lateral geniculate nuclei of these animals by methods that have been reported previously (Guillery and Kaas, '71). At the end of each recording experiment the brains were fixed in formol saline, cut as frontal or sagittal frozen sections at 50 μ and stained with cresyl violet. This material provided information on the visuotopic organization of the lateral geniculate nucleus in these species and, on the basis of this, the position of the cellular discontinuities could be related to the geniculate representation of the optic disc.

Finally, a number of cat brains were available from animals that had had one eye removed 3–13 days before death. These were cut as frontal or sagittal sections at 45 μ and were stained by the Nauta-Gygax ('54) or Fink-Heimer ('67) methods.

RESULTS

Cellular discontinuities that correspond to the representation of the optic disc have been found in geniculate layers in members of four mammalian orders. We have not attempted a more complete survey of the mammalian orders, but have studied only those brains that show clear signs of lamination and that were available to us as a complete series cut in an appropriate plane. The occurrence of one or more discontinuities in each of the species we describe here suggests that similar discontinuities can also be found in other mammalian species.

1. *Carnivores.* In lamina A of the domestic cat, the cellular discontinuity that corresponds to the optic disc has been described previously (Guillery and Kaas, '71). The discontinuity can be seen in sagittal or frontal sections about halfway between the rostral and caudal poles of the nucleus and about two thirds of the way between the medial and lateral margins. It is 100μ–200μ in diameter and has been found in every normal adult cat that we have examined. In many sections, one sees a slight broadening of layer A1 opposite the discontinuity, so that some of the A1 cells protrude a short distance into the ventral aspects of layer A.

In Nissl sections through a normal cat's nucleus it is not possible to distinguish a corresponding discontinuity within layer C (see Guillery, '70, for details of the laminar terminology). This layer is narrower than layer A and, especially in the region opposite the discontinuity in A, the large cells that characterize layer C are rather scattered. In sections stained for degenerating retinogeniculate axons, the zone of dense pericellular degeneration that marks layer C contralateral to the lesion is interrupted (see fig. 1). In the small region that is free of degenerating axons there are generally one or two cells, but it has not been possible to determine whether these belong to layer C or to one of the adjacent layers. Thus, in the lateral geniculate nucleus of the domestic cat, each of the two layers that receives afferents from the nasal retina shows a distinct interruption, either of the cells or of the afferent plexus.

Although we cannot obtain electrophysiological recordings from the animals in which the retinogeniculate fiber degeneration is shown, we have found that the discontinuity in layer C lies in the part of the lamina that receives from the region of the optic disc. Further, the discontinuity is aligned, along the lines of projection, with the discontinuity in layer A (see fig. 1). Thus, it is reasonable to conclude that the part of layer C that is free of retinogeniculate fibers represents the region of the optic disc.

After finding the discontinuity in layer A of the lateral geniculate nucleus of the domestic cat, it was easy to find a similar discontinuity in layer A of other carnivores since the basic structure of the nucleus is



Fig. 1 Retinogeniculate fiber degeneration in the lateral geniculate nucleus of a cat that survived five days after a removal of the contralateral eye. A part of a coronal section stained by the Nauta-Gygax method is shown. Medial is to the left. The unlabelled arrow shows the edge of the discontinuity in layer A and the discontinuity in layer C is seen slightly lateral to this.

the same in all the carnivores that we have studied. When we found the discontinuity in the appropriate region we felt confident that it was related to the optic disc, even without electrophysiological confirmation. This interpretation is strengthened by our inability to find more than one well defined discontinuity in any of the geniculate layers.

The discontinuity in layer A of the lateral geniculate nucleus of the African lion (*Panthera leo*) is shown in figure 2. From the slight inclination of the discontinuity that is seen in the coronal section it is apparent that the complete discontinuity cannot be shown in a single sagittal section. Thus, only its lower part is shown in the sagittal section.

Several conclusions can be drawn about the visual system of the lion, and they are given here in order to illustrate the way in which information about the cellular discontinuity can be used. In the first place, the most dorsal layer of the lateral geniculate nucleus must represent the contralateral nasal retina. Second, the lines of projection near the discontinuity must run parallel to the cylinder that it forms. Third, since the medial margin of the nucleus, formed by the full complement

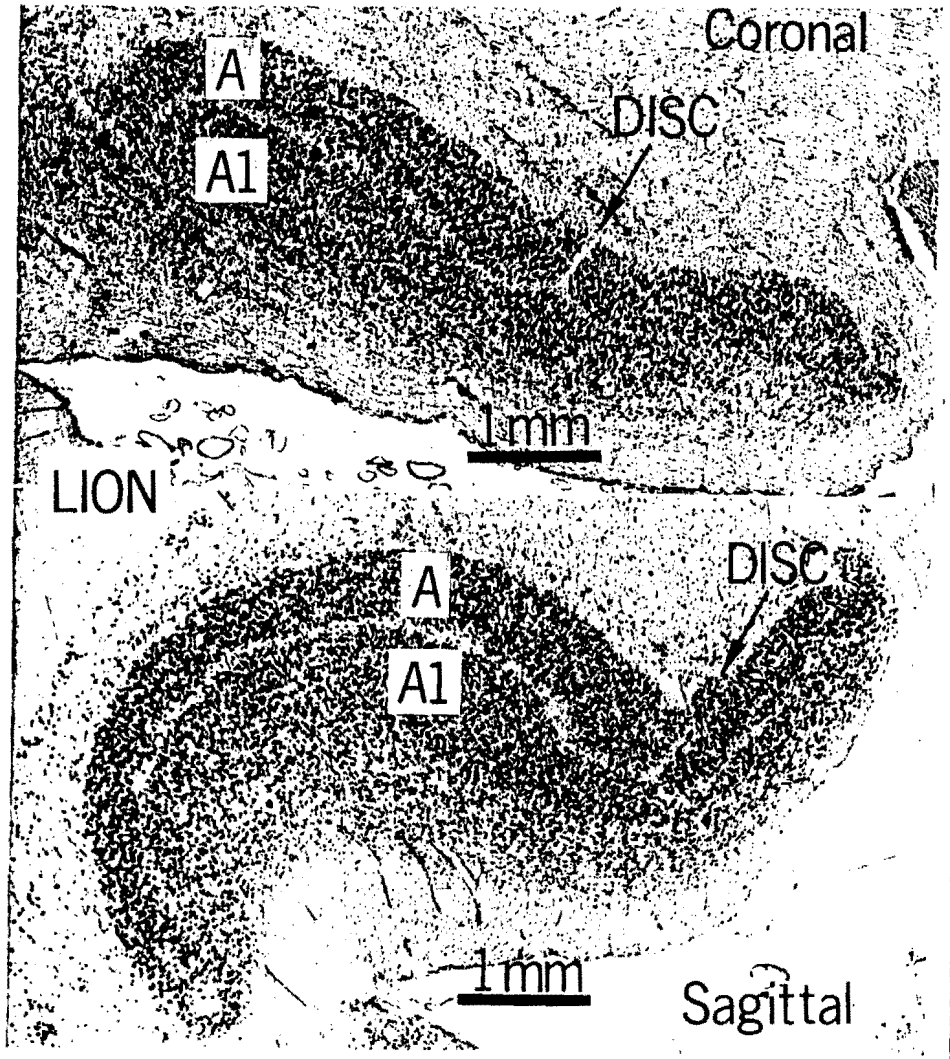

Fig. 2 The lateral geniculate nucleus of a lion in coronal and sagittal sections. The cellular discontinuity in layer A (DISC) is shown. Medial is to the left in the upper figure and rostral is to the left in the lower figure. Thionin stain.

of relay laminae, probably corresponds to the representation of the "line of decussation" or zero vertical meridian (Kaas et al., '72a) the segment of the lateral geniculate nucleus that lies medial to the cellular discontinuity in the lion must represent the portion of the visual field between the blind spot and the zero vertical meridian.

This last point allows comparison of the visual field representations in the lion and cat. In previous experiments (Kaas, Hoffmann, and Ladpli, unpublished observations) the optic disc and area centralis of the retina of two lions were projected onto a screen[1] and a zero vertical meridian was drawn through the area centralis. In both animals the horizontal visual angle between the vertical meridian and the blind spot was 15°–16°, which is close to the corresponding angle in the domestic cat (Bishop et al., '62). The part of the lateral geniculate nucleus lying medial to the cellular discontinuity thus represents the same visual angle in the cat and the lion. Since this part forms a relatively larger proportion of the total mediolateral extent of the nucleus in the lion than it does in the cat, one can conclude that the lion has a somewhat greater relative representation of central vision in the lateral geniculate nucleus. This is to be expected since the lion is less adapted for nocturnal vision. For example, the lion has a thinner and less reflective tapetum lucidum and also has the circular pupil typical of diurnal animals (Walls, '42).

In agreement with the deductions that can be made about the lateral geniculate nucleus, it has been found that proportionately more of the striate cortex is devoted to central vision in the lion than in the cat (Kaas, Hoffman and Ladpli, unpublished observations).

The cellular discontinuity in layer A can also be readily identified in several other carnivores. Three of these, a puma (*Felis concolor*), a leopard (*Panthera pardus*) and an infant tiger (*Panthera tigris*) are shown in figure 3. In each of these sections, and also in figure 2, the slight thickening of layer A1 that occurs opposite the cellular discontinuity is evident. The sections suggest that in the puma the relative geniculate representation of central vision resembles that of the domestic cat, while the leopard is more like the lion in this respect. The section from the tiger is not readily compared. Since the individual was an infant, the geniculate cells are still quite closely packed and, further, the plane of this section does not closely correspond to the plane in which the other nuclei were cut.

It is apparent from figures 2 and 3 that layers C and C1 are thin and difficult to distinguish from each other in the adult *Panthera*. Therefore we did not expect to be able to detect a discontinuity in layer C in these normal brains and we were not able to do so. However, the relative thickness of the C layers appears to depend upon the age of the individual, since separate C and C1 layers are easily distinguished in the infant tiger (fig. 3) and also in the brain of an infant lion that we have studied. In the infant tiger a discontinuity can be seen in layer C. Mediolaterally this is aligned with the discontinuity in layer A but it lies slightly caudal to the level of figure 3. The brain of the infant lion was not sectioned in a plane useful for revealing the discontinuity in either layer A or layer C.

Outside the cat family we have also identified the cellular discontinuity in layer A of the lateral geniculate nucleus of the mink (*Mustela vison*) and the weasel (*Mustela rixosa*). In these brains there is a curious duplication of the A and A1 layers (Sanderson, Kaas and Guillery, unpublished observations) and one finds that the cellular discontinuity forms a continuous cylindrical interruption through both of the A layers.

2. *Primates*. Serial microelectrode punctures through the dorsal lateral geniculate nucleus of the owl monkey (*Aotus trivirgatus*), which are reported separately (Kaas et al., '72a) have shown the part of the nucleus in which one can expect to find the representation of the optic disc. Figure 4 shows that in the appropriate part of the nucleus there is a well defined cellular discontinuity in the external magnocellular layer, while figure 5 shows a somewhat less obvious discontinuity in the external parvocellular layer. The latter passes somewhat obliquely to the plane of the sections so that its full extent is not seen in any one of the sections. However, it is invariably found in the same part of the nucleus and does not enter the internal parvocellular layer in any of the sections. Since the external layers receive from the contralateral nasal retina, while the internal layers receive from the ipsilateral temporal retina (Jones, '66; Kaas et al., '72a), the conclusion that these discontinuities do, indeed, represent the optic

[1] These observations were made while the lions were anesthetized and in this they differ from the more courageous observations made by Johnson ('68).

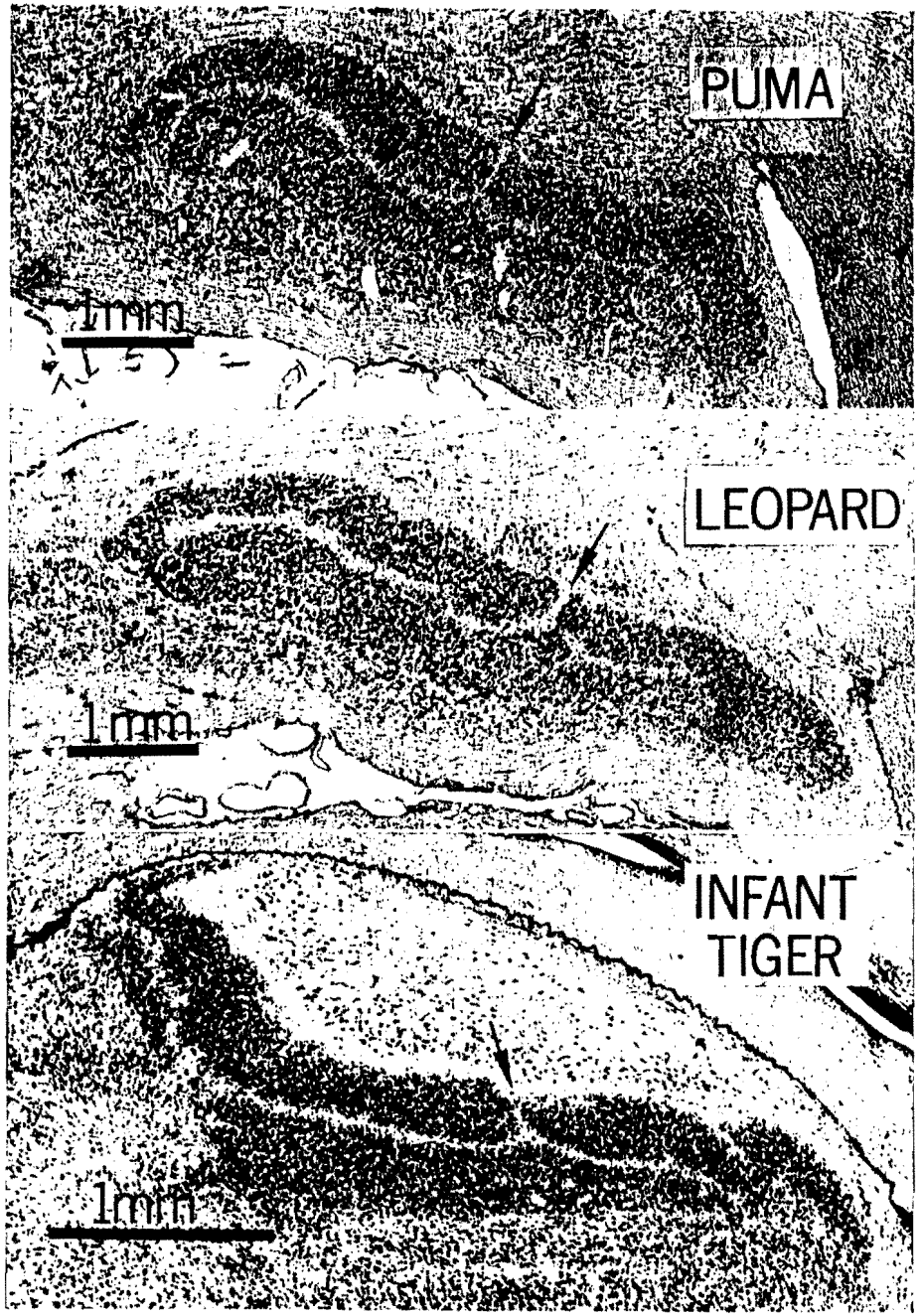

Fig. 3 Three coronal sections through the lateral geniculate nucleus of a puma, a leopard and a ten-day old infant tiger. Medial is to the left in each of the figures. The cellular discontinuity in layer A is shown by unlabelled arrows. Thionin stain.



Fig. 4 The lateral geniculate nucleus of an owl monkey shown in a sagittal section. Caudal is to the left. The external and internal parvocellular (PE & PI) and magnocellular (ME & MI) layers and the superficial (S) layer have been labelled. The cellular discontinuity in the external magnocellular layer is shown by an unlabelled arrow. Thionin stain.

disc, seems well justified. Since the optic disc is about 20° from the line of decussation of the retina (Jones, '66; Allman and Kaas, '71) and since the caudal margin of the lateral geniculate nucleus represents the region of the line of decussation, it follows that the portion of the lateral geniculate nucleus between the discontinuity and the caudal margin (see fig. 4) represents a central 20° of horizontal visual angle.

In the rhesus monkey (*Macaca mulatta*), preliminary study has also shown cellular discontinuities that appear to correspond to the optic disc. Kaas et al. ('72a) have recently considered the laminar structure in old world monkeys and have suggested that "layers," which represent a complete hemiretina, be distinguished from "leaflets," which represent only the central portions of the retina. Thus, two parvocellular layers split and in the more central parts of the representation they form four parvocellular leaflets. It appears that the representation of the optic disc lies close to the region where the two parvocellular layers split to form four interlacing leaflets. There is a well defined cellular discontinuity in the lateral part of the dorsal leaflet (layer 6) of the external parvocellular layer. So far we have not found a discontinuity in the ventral leaflet (layer 4) of the external parvocellular layer. In the relevant part of the nucleus, the parvocellular layers tend to be pierced by transverse fiber bundles, and the interdigitation of the leaflets makes identification of interruptions in the cell layers difficult.

The lateral geniculate nuclei of several prosimians, including the slow loris (*Nycticebus coucang*) and Galago (*Galago crassicaudatus*), have been described as consisting of six main layers (Chacko, '54; Ionescu and Hassler, '68; Ionescu, '69; Campos-Ortega and Hayhow, '70; Laemle and Noback, '70; Tigges and Tigges, '70). Since layers 1, 5, and 6 are reported to receive projections from the contralateral eye, one would expect discontinuities in

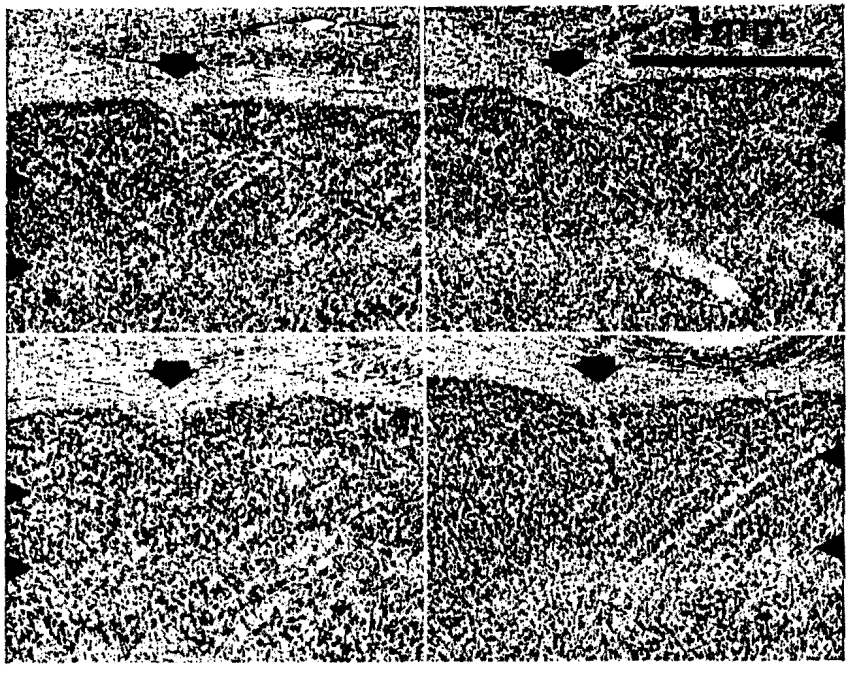

Fig. 5 Sagittal sections through the lateral geniculate nucleus of four owl monkeys. The borders of the internal parvocellular layers are shown by small triangles and the cellular discontinuities in the external parvocellular layers are shown by the large arrows. Thionin stain.

these three layers. The position of the discontinuity in the lateral geniculate nucleus of a slow loris is shown in a horizontal section in figure 6. The plane of the section reveals the discontinuity in only a part of layer 6 and not in layers 5 and 1. Four more examples of the discontinuity in layer 6 are seen in figure 7. In three of the photomicrographs in figure 7 the discontinuity extends through layer 6 and into at least a part of layer 5. In the lower right photomicrograph in figure 7 the plane of the section does not show the discontinuity in layer 5, but a complete interruption of layer 5 is apparent in adjacent sections. The discontinuity in layer 5 is less obvious, because this layer is thinner and less densely packed with cells than layer 6. The discontinuity in layer 1 of the lateral geniculate nucleus of the slow loris is shown in figure 8. It lies approximately in line with the discontinuities in layers 5 and 6.

In the lateral geniculate nucleus of Galago, cellular discontinuities are also found in layers 1, 5 and 6. The discontinuities are narrower than in the slow loris but occur in about the same part of the nucleus. The discontinuity in layer 6 is shown in figure 9. The discontinuities in layers 1, 5 and 6 can also be seen in figure 2B of Ionescu's ('69) report. Since these discontinuities in the layers of the slow loris and bush baby are aligned along a line that runs roughly perpendicular to the layers, they are reasonably regarded as representations of the optic disc.

Other mammals. A discontinuity is also apparent in the lateral geniculate nucleus of at least one rodent and one marsupial. In normal Nissl stained sections, the lateral geniculate nucleus of the squirrel is



Fig. 6 The lateral geniculate nucleus of a slow loris in a horizontal section. Medial is to the left. The six layers are numbered and the cellular discontinuity in layer 6 is shown by a large arrow. The other discontinuities are not included in this section. Thionin stain.

visibly laminated. The laminar structure of the nucleus has been described elsewhere (Kaas et al., '72a,b). In brief, there are three rostrocaudal cell groups or layers separated by two narrow mediolateral interlaminar cell-poor zones (see fig. 10). These interlaminar zones do not extend into the lateral third of the nucleus but join to define the lateralmost extent of layer 2, which receives projections from the ipsilateral retina.

Just ventral to the midportion of the nucleus, layer 1 shows a discontinuity which meets the junction of the interlaminar zones (fig. 10). Layer 1 receives projections from the contralateral eye and the discontinuity is oriented along the lines of projection (Kaas et al., '72a,b), so that it seems reasonable to conclude that the optic "disc" is related to this discontinuity. However, the optic nerve head in the squirrel is a strip that is elongated in the horizontal plane rather than a disc (Johnson, '01; Walls, '42). Blood vessels radiate outward from a disc-like enlargement at each end of the optic strip and in earlier experiments it was noted that the blind spot caused by the temporal enlargement is near the temporal margin of the binocular portion of the visual field while the blind spot caused by the nasal enlargement is well into the monocular field (Hall et al., '71). The cylindrical discontinuity in layer 1 may correspond to only the temporal enlargement of the optic strip, since the discontinuity occurs just at the margin of the binocular segment of the lateral geniculate nucleus.

The third cell group in figure 10 is not a single layer but consists of three concealed layers. A middle layer of ipsilateral input is bordered rostrally and caudally by layers of contralateral input (Kaas et al., '72b). These layers of contralateral input are thin and were too poorly defined to allow the identification of a discontinuity.

The cytoarchitecture of the lateral geniculate nucleus of the marsupial phalanger (*Trichosurus vulpecula*) has been described by Hayhow ('67). Four layers are apparent, although fiber degeneration

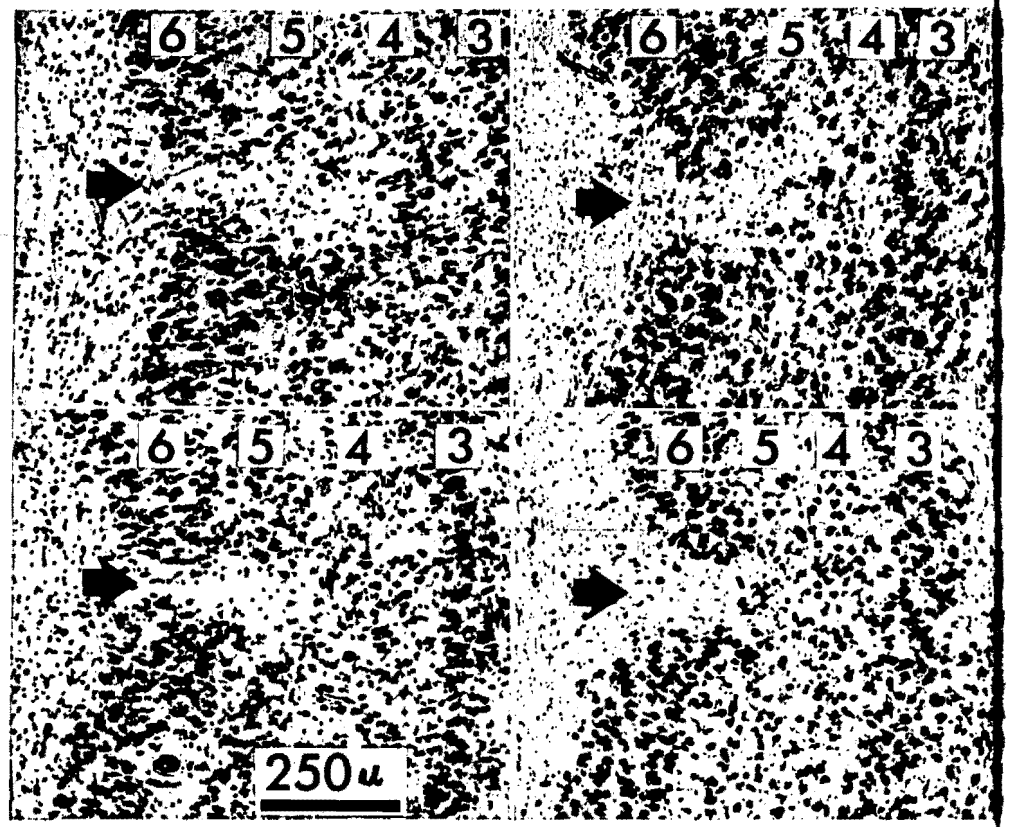

Fig. 7 The cellular discontinuities in layers 5 and 6 of four lateral geniculate nuclei of the slow loris are shown by unlabelled arrows. Sagittal sections; thionin stain. Rostral is left.

methods reveal that two can be further subdivided into concealed layers (Hayhow, '67). Of the two single layers that are histologically distinct one receives ipsilateral retinogeniculate projections (number 4) and one receives contralateral retinogeniculate fibers (number 3). A discontinuity is clearly evident in layer 3 (fig. 11) and electrophysiological recordings show that this discontinuity corresponds to the optic disc (fig. 12). No discontinuity was seen in any of the concealed layers.

DISCUSSION

It has been shown that in many species there is a cellular discontinuity in some of the geniculate layers. Electrophysiological evidence shows that these discontinuities lie in the part of the lateral geniculate nucleus that is innervated by ganglion cells adjacent to the optic disc. Since the cellular discontinuities were well marked in all of the species we have studied in detail, it seems probable that they can also be found in many other mammalian species. We have shown how, as an isomorph of a retinal landmark, the discontinuity can be useful for predicting some aspects of the gross retinotopic organization of the lateral geniculate nucleus. The functional significance of

Fig. 8 The cellular discontinuity in layer 1 of the lateral geniculate nucleus of a slow loris is shown by an arrow. The layers are numbered 1–6. OT: optic tract. Sagittal section; thionin stain. Rostral is left.

the discontinuity itself may prove of more basic interest, as may the mechanism by which the discontinuity develops.

It is clear, from the occurrence of the discontinuity, that geniculate neurons are very precisely placed in relation to the retinal origin of their innervation. This topographically precise arrangement of the geniculate cells may represent either interlaminar or intralaminar mechanisms. An interlaminar mechanism would be involved if, as suggested by Bishop et al. ('62), the representations of homonymous retinal points in adjacent geniculate layers are accurately aligned so that the lines of projection are really straight lines. Since only one hemiretina has a hole, there must then be a hole in one set of the geniculate layers. However, the discontinuity may not relate to the ineraction of the two eyes at all. The lines of projection could, in principle, be bent in the regions that represent the optic disc. In this case the intralaminar distribution of geniculate cells may so accurately reflect the spacing of the retinal receptor elements that receptors separated by the optic disc are represented by geniculate cells that are separated from each other by a cellular discontinuity.

On the second interpretation, lateral interactions between geniculate neurons would be critically dependent on spatial arrangements that preserve the retinotopic organization. If this is the case then the occurrence of the cellular discontinuity, and its size, may differ with particular adaptations of cetrain species or with the special functions of certain geniculate layers. One can wonder, for example, why the cellular discontinuity is wide in the slow loris and narrow in Galago. This



Fig. 9 The cellular discontinuity in layer 6 of four lateral geniculate nuclei of Galago is shown by unlabelled arrows. Sagittal sections; thionin stain. Rostral is left.

may be related to visual acuity or to some other aspect of visual function.

The observations that we have made in the squirrel suggest that in this species the cellular discontinuity is related to interlaminar mechanisms. It has been shown that the optic nerve head in this species shows a temporal and a nasal enlargement, but that only one of the "two blind spots," the one that lies in the binocular part of the visual field, is represented by a cellular discontinuity in the lateral geniculate nucleus. If intralaminar mechanisms were relevant one would expect to see a second discontinuity in the monocular part of the nucleus.

In the several species studied here the cellular discontinuities are rarely more than 100 to 200 μ in diameter. They are thus not much larger than some of the blood vessels and fiber bundles that commonly traverse parts of the nucleus. If geniculate organization requires the precise positioning of nerve cells, then some compensation must be made for displacements caused by blood vessels and fiber bundles. It is not known how this is achieved, nor is anything known at present about the development of the very precise geniculate representations. A relevant point that arises from the present material is that a cellular discontinuity



Fig. 10 The cellular discontinuities in layer 1 of the lateral geniculate nucleus of four squirrels are shown by thick arrows. The discontinuity lies close to the lateral edge of layer 2 and fuses with the interlaminar zones marked by thin arrows on either side of layer 2. Horizontal sections. Lateral is right, rostral below; thionin stain.

was found in a ten-day old infant tiger that can have had little if any visual experience. Thus, the discontinuity can be developed without visual experience. It remains to be determined whether the discontinuity can be modified postnatally by visual deprivation or geniculate denervation.

There are some geniculate nuclei or layers in which we have not seen a cellular discontinuity in the expected place. In some instances this may have been because in the brains that were available to us only every 5th section had been mounted. In others it may have been because the cylindrical discontinuity was oriented oblique to the plane of the available sections. It is possible that in some brains the discontinuity is obscured by fiber bundles or blood vessels that interrupt the layers, as may have been the case for layer 4 of the macaque. We have

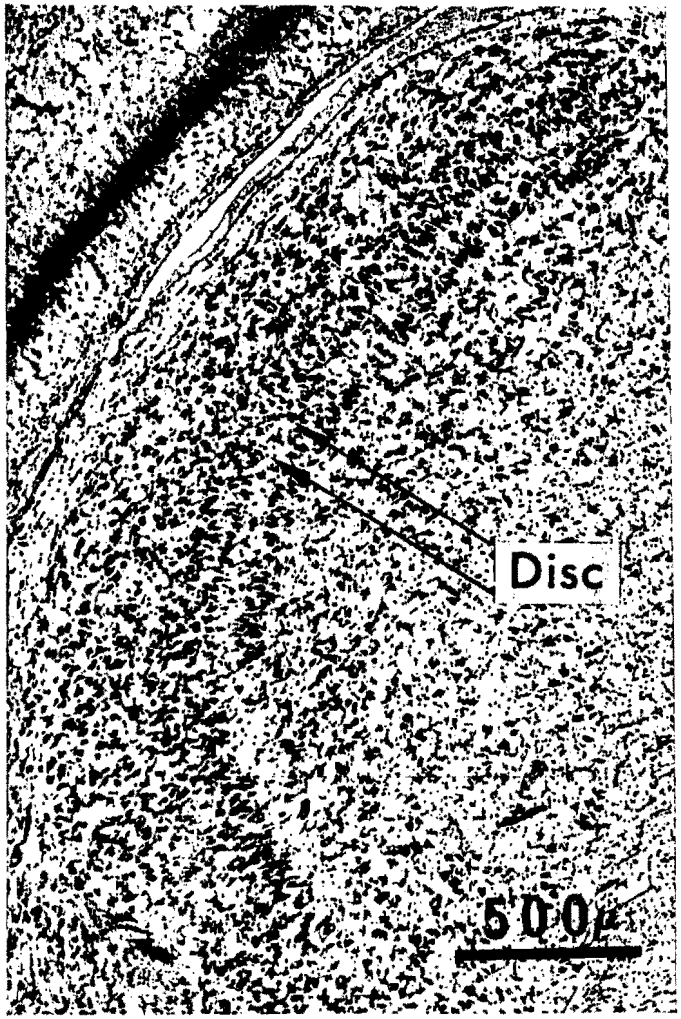

Fig. 11 Coronal section through the lateral geniculate nucleus of a marsupial phalanger, showing the cellular discontinuity in layer 3 (see fig. 12). Frontal section. Thionin stain.

shown that in some layers, such as layer C of the cat, the cells are too sparse to show a clear discontinuity in the Nissl stained sections. In these layers the discontinuity can sometimes be revealed by the distribution of degenerating retinogeniculate axons. Some geniculate layers are folded in a complex fashion and it is then extremely difficult to identify a clear discontinuity and distinguish it from a tangential section through one of the folds. The lateral part of layer A in some dogs shows this complex folding, especially where the monocular segment of the nucleus is large.

It is not necessary to conclude, from

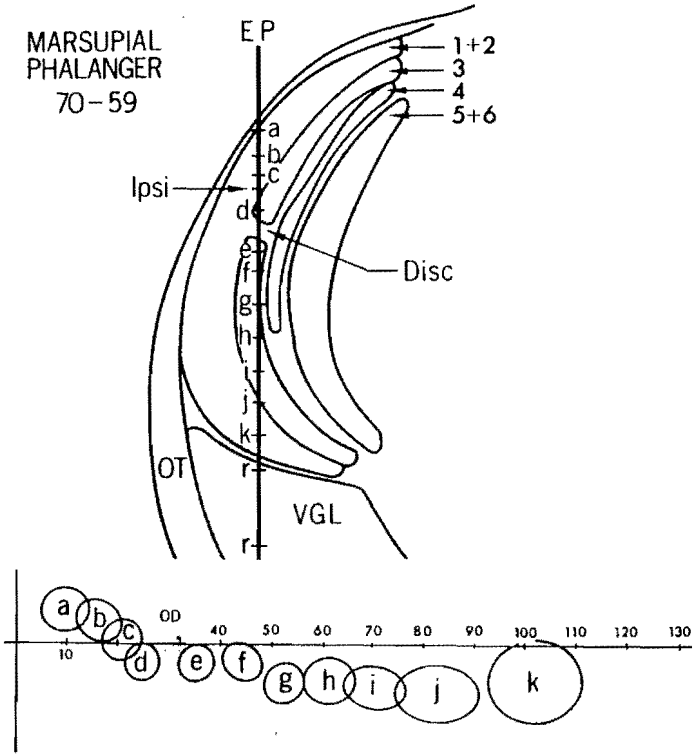

Fig. 12 The locations of receptive fields for recording sites in the lateral geniculate nucleus of a marsupial phalanger. Receptive fields d and e are adjacent to the projection of the optic disc (OD) into the visual field and correspond to recording sites d and e which are adjacent to the discontinuity (Diso) in layer 3 of the lateral geniculate nucleus. Above: a coronal section with a microelectrode puncture (EP). Recording sites are indicated by horizontal bars (a-k). The unlettered recording site (ipsi) was activated by stimuli to the ipsilateral eye. Receptive fields for recording sites (r) in the ventral lateral geniculate nucleus (VGL) are not shown. OT: optic tract. Below: a portion of the contralateral visual hemifield with temporal to the right. The vertical bar indicates the approximate projection of the line of decussation of the retina which was, however, not accurately defined. A horizontal reference line is drawn through the projection of the optic disc (OD) and this is marked in 10° segments. The lettered circumscribed areas indicate receptive fields corresponding to the labeled recording sites above.

present day knowledge of geniculate mechanisms, that the optic disc will always be represented by a cellular discontinuity in the lateral geniculate nucleus. Some types of geniculate organization may require a spatial separation of cells that are innervated by non-adjacent parts of the retina, while the spatial arrangement of geniculate cells may be less important for other types of organization. Thus, as one examines a variety of species it may prove that some geniculate nuclei, or layers, may have a well marked discontinuity while others may have none. In order to demonstrate that there are layers with no discontinuity it will be necessary to make serial microelectrode punctures and determine the part of the nucleus related to the optic disc. Then that part of the nucleus can be studied by the Nissl and Nauta methods.

In the species that we have studied elec-

trophysiologically we have been able to demonstrate the discontinuity in every appropriate layer that is histologically well defined. However, in the grey squirrel, the most caudal of the cell layers that are recognizable in Nissl material actually consists of three concealed layers, two of which receive afferents from the contralateral eye (Kaas et al., '72). A discontinuity is not apparent in either of these concealed layers. Nor is there a discontinuity in the concealed layers of the marsupial phalanger. Similarly, in preliminary observations, we have been unable to identify a cell-free region that might correspond to the optic disc in the lateral geniculate nuclei of rabbits and rats. The nuclei in these mammals consist of concealed rather than cytoarchitectonically distinct layers (Giolli and Guthrie, '69; Hayhow et al., '62; Guillery et al., '71). It is possible that, in general, concealed layers show no cellular discontinuity, while the cytoarchitectonically distinct layers do show this feature.

ACKNOWLEDGMENTS

We thank Mrs. E. Langer and Mr. T. Stewart for the photography, Mrs. D. Urban for drawing figure 12, and Mrs. J. Eckleberry, Mrs. I. Lucey, and Mrs. B. Yelk for preparing histological materials. We are grateful to Dr. I. T. Diamond for providing several marsupial phalangers.

LITERATURE CITED

Allman, J. M., and J. H. Kaas 1971 A representation of the visual field in the caudal third of the middle temporal gyrus of the owl monkey (*Aotus trivirgatus*). Brain Research, *31:* 85–105.

Bishop, P. O., W. Kozak, W. R. Levick and G. J. Vakkur 1962 The determination of the projection of the visual field on the lateral geniculate nucleus in the cat. J. Physiol. (Lond.), *163:* 503–539.

Campos-Ortega, J. A., and W. R. Hayhow 1970 A new lamination pattern in the lateral geniculate nucleus of primates. Brain Research, *20:* 335–339.

Chacko, L. W. 1954 The lateral geniculate body in lemuroidea. J. Anat. Soc. Ind., *3:* 24–35.

Fink, R. P., and L. Heimer 1967 Two methods for selective silver impregnation of degenerating axons and their synaptic endings in the central nervous system. Brain Res., *4:* 369–374.

Giolli, R. A., and M. D. Guthrie 1969 The primary optic projections in the rabbit. An experimental degeneration study. J. Comp. Neur., *36:* 96–126.

Guillery, R. W. 1967 Patterns of fiber degeneration in the dorsal lateral geniculate nucleus of the cat following lesions in the visual cortex. J. Comp. Neur., *130:* 197–213.

——— 1970 The laminar distribution of retinal fibers in the dorsal lateral geniculate nucleus of the cat: A new interpretation. J. Comp. Neur., *138:* 339–368.

Guillery, R. W., and J. H. Kaas 1971 A study of normal and congenitally abnormal retinogeniculate projections in cats. J. Comp. Neur., *143:* 73–100.

Guillery, R. W., C. Sitthi Amorn and B. B. Eighmy 1971 Mutants with abnormal visual pathways: an explanation of anomalous geniculate laminae. Science, *174:* 831–832.

Hall, W. C., J. H. Kaas, H. Killackey and I. T. Diamond 1971 Cortical visual areas in the grey squirrel (*Sciurus carolinensis*): a correlation between cortical evoked potential maps and architectonic subdivisions. J. Neurophysiol., *34:* 437–452.

Hayhow, W. R. 1967 The lateral geniculate nucleus of the marsupial phalanger, *Trichosurus vulpecula*. An experimental study of cytoarchitecture in relation to the intranuclear optic nerve projection fields. J. Comp. Neur., *131:* 571–604.

Hayhow, W. R., A. Sefton and C. Webb 1962 Primary optic centers in the rat in relation to the terminal distribution of the crossed and uncrossed optic nerve fibers. J. Comp. Neur., *118:* 295–322.

Ionescu, D. A. 1969 Post-primary flash-evoked responses in unanesthetized night- and day-active monkeys. Exp. Brain Res., *7:* 275–298.

Ionescu, D. A., and R. Hassler 1968 Six cell layers in the lateral geniculate body in the night-active prosimian, *Galago crassicaudatus*. Brain Research, *10:* 281–284.

Johnson, G. L. 1901 Contributions to the comparative anatomy of the mammalian eye, chiefly based on ophthalmoscopic examination. Phil. Trans. Roy. Soc., B., *194:* 1–82.

——— 1968 Ophthalmoscopic studies on the eyes of mammals. Phil. Trans. Roy. Soc., B., *254:* 207–220.

Jones, A. E. 1966 The lateral geniculate complex of the owl monkey, *Aotes trivirgatus*. J. Comp. Neur., *126:* 171–180.

Kaas, J. H., R. W. Guillery and J. M. Allman 1972a Some principles of organization in the dorsal lateral geniculate nucleus. Brain, Behavior and Evolution. (In press)

Kaas, J. H., W. C. Hall and I. T. Diamond 1972b Visual cortex of the grey squirrel (*Sciurus carolinensis*): Architectonic subdivisions and connections from the visual thalamus. J. Comp. Neur., *145:* 273–306.

Laemle, L. K., and C. R. Noback 1970 The visual pathways of the lorisid lemurs (*Nycticebus coucang* and *Galago crassicaudatus*). J. Comp. Neur., *138:* 49–62.

Nauta, W. J. H., and P. A. Gygax 1954 Silver impregnation of degenerating axons in the central nervous system: A modified technic. Stain Tech., *29:* 91–93.

Thuma, B. D. 1928 Studies on the diencephalon of the cat. I. The cytoarchitecture of the corpus geniculatum laterale. J. Comp. Neur., *46:* 173–200.

Tigges, M., and J. Tigges 1970 The retinofugal fibers and their terminal nuclei in *Galago crassicaudatus* (Primates). J. Comp. Neur., *138:* 87–102.

Walls, G. L. 1942 The vertebrate eye and its adaptive radiations. The Cranbrook Institute of Science, Bloomfield Hills, Michigan, 1942.